

Ouachita Baptist University

Scholarly Commons @ Ouachita

Honors Theses

Carl Goodson Honors Program

2009

Achieving Emmetropia through Astigmatic Keratotomy

Abby Kauffman Brumley
Ouachita Baptist University

Follow this and additional works at: https://scholarlycommons.obu.edu/honors_theses



Part of the [Medicine and Health Sciences Commons](#)

Recommended Citation

Brumley, Abby Kauffman, "Achieving Emmetropia through Astigmatic Keratotomy" (2009). *Honors Theses*. 19.

https://scholarlycommons.obu.edu/honors_theses/19

This Thesis is brought to you for free and open access by the Carl Goodson Honors Program at Scholarly Commons @ Ouachita. It has been accepted for inclusion in Honors Theses by an authorized administrator of Scholarly Commons @ Ouachita. For more information, please contact mortensona@obu.edu.

SENIOR THESIS APPROVAL

This Honors thesis entitled

“Achieving Emmetropia through Astigmatic Keratotomy”

written by

Abby Kauffman Brumley

and submitted in partial fulfillment of the
requirements for completion of the
Carl Goodson Honors Program
meets the criteria for acceptance
and has been approved by the undersigned readers.

(Dr. Marty Perry) thesis director

(Dr. Lori Hensley) second reader

(Mr. Glenn Good) third reader

honors program director

April 15, 2009

**ACHIEVING EMMETROPIA THROUGH
ASTIGMATIC KERATOTOMY**

ABBY KAUFFMAN BRUMLEY

April 15, 2009

TABLE OF CONTENTS

I. INTRODUCTION.....	3
II. BACKGROUND ON ASTIGMATISM.....	6
III. DIAGNOSING AND CORRECTING ASTIGMATISM.....	10
IV. BACKGROUND ON CATARACTS.....	13
V. PRE-OPERATIVE CATARACT SURGERY PROCEDURE.....	16
A. <i>Refractometry</i>	17
B. <i>Indirect Examination</i>	18
C. <i>Anterior Examination</i>	19
D. <i>Intraocular Pressure Check</i>	20
VI. METHOD OF REGULAR CATARACT SURGERY.....	25
VII. METHOD OF “REFRACTIVE” CATARACT SURGERY.....	28
VIII. CONCLUSIONS.....	32
IX. REFERENCES.....	35

I. INTRODUCTION

An estimated 1 in 6 people have a degree of the debilitating eye disorder known as astigmatism.¹ A condition typically developed between the ages of birth and four years, corneal astigmatism is caused by irregular development of the cornea and results in blurred near and far vision. However, in addition to the onset of astigmatism early in life due to irregular development of the cornea, patients also commonly face the development of a condition known as a cataract, which is a condition common to adults over the age of 65 that is classified by a gradual expansion in opacity of the crystalline lens of the eye. Cataracts are the current leading cause of blindness worldwide and account for the majority of decreased visual acuity of patients in the United States.² The concurrence of both the debilitating eye disorder astigmatism and the development of cataracts with age can lead to dramatic decreases in day-to-day function of the elderly if not combated by modern surgical practices. Cataract surgery has become one of the most common elective procedures across the globe; Medicare alone spent an estimated 60% of their funding on routine cataract surgery procedures during the 1990s.¹ Up until the late twentieth century, nearly all cataract surgery patients had to get glasses following their operations. But with the exciting new development of a procedure called astigmatic keratotomy, there is the chance that astigmatic patients could see without compensating cylindrical lenses post-surgery.

Scientifically known as phacoemulsification, cataract surgery is not a procedure that would be considered an advancement of the modern world. Along with having been great innovators in architecture and engineering through the development of advancements such as paved roads and the building of aqueducts, the Romans also

proved to have been highly advanced in their development of medical treatments, particularly in the field of ocular disease. Through archeological investigations of ancient relics of the Roman Empire, such as at the Roman city of Uriconium at Wroxter in present day England, and written accounts by the Roman writer Aulus Cornelius Celsus, the earliest known successful cataract surgeries have been documented to have taken place during ancient Roman times. Crude needles discovered in the ruins of Uriconium are believed to have been used for cataract removal in ancient surgeries. Also, the writings of Celsus include descriptions of procedures known as “couchings,” which are similar to semi-rudimentary forms of modern day cataract removals using fine tools and antiseptics of copper oxide and vinegar. Besides early accounts of eye surgery across the Roman Empire, there is evidence of ancient physicians of China, India, and Greece developing similar techniques to increase the visual acuity of patients suffering from cataracts.³

In the 18th century, the French were the first to suggest opening up the eye for surgery to increase vision of diseased patients in a procedure called intracapsular cataract surgery. In intracapsular cataract surgery, a large incision is used to remove the cloudy lens;⁴ however, with the innovation of using ultrasound to break up the cataract by Charles Kelman in 1967, it became possible for ophthalmologists to conduct small-incision surgeries that posed fewer risks. Prior to the 1980s, the primary objective of ophthalmologists in cataract surgery was to carry out the smoothest technique for removal of the degraded lens. The focus was on achieving the best spectacle-corrected visual acuity (BSCVA), rather than achieving the best uncorrected visual acuity (UCVA)

known as emmetropia, the ideal condition of an eye in which no correction is needed to achieve a sharp focus.⁵

The suggestion of a transition of attention from BSCVA to UCVA in cataract surgery was heralded as a revolutionary move by the leading ophthalmic community of the 1980s. Dr. Robert H. Osher of the Cincinnati Eye Institute is someone akin to a modern day Galileo, having been the ophthalmologist to take the first initiative to propose the concept of refractive cataract surgery with astigmatic keratotomy. Despite his initial successes to show a marked improvement in post-operation visual acuity from utilizing his new techniques, Dr. Osher was met with harsh criticism from the leaders of his field when presenting his findings. Osher noted that they went so far as to say that he was attempting “to play God by interfering with the sacred cornea.” However, despite the opinion of his peers, by making the step toward focusing on total vision correction, rather than simple lens replacement, Osher opened the gateway for further innovation to achieve emmetropia through astigmatism correction during cataract surgery.⁶

II. BACKGROUND ON ASTIGMATISM

A person is able to form an image of the setting that is before them, because as light enters the eye, it passes through the cornea, and then the lens directs the rays of light to come to focus at a single point

called the focal point (Figure 1).

In order for the eye to form a crisp image, the light rays must come to focus on the back curved surface of the eye called the retina, which contains a series of nerves and receptors called rods and cones that direct sensory

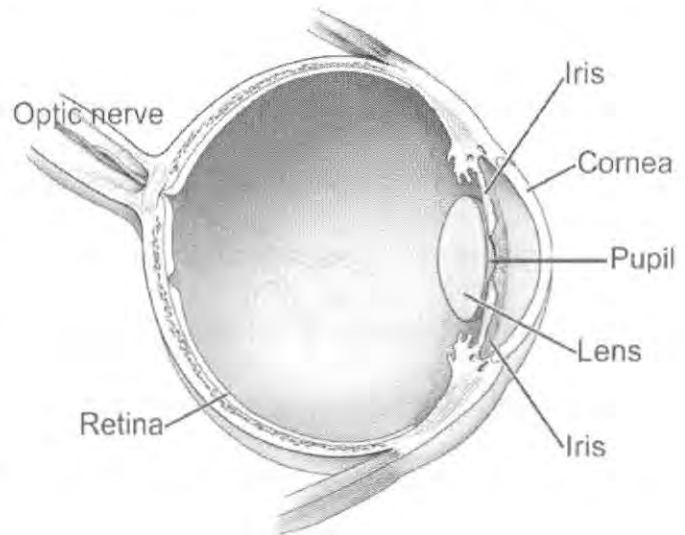


Figure 1. THE ANATOMY OF A HUMAN EYE⁴

input through the optic nerve to the brain for processing. The cause of blurred vision is light rays entering the eye that don't come to focus on the retina.⁷

There are three routine cases of blurred vision in patients – myopia, hyperopia, and astigmatism. More commonly known as nearsightedness, myopia is a condition caused by the development of an eye that is too long. Added length to the eye causes the retina to be farther away from the lens than is normal; therefore, the rays of light entering the eye through the pupil come to focus at a point in front of the retina. Myopia allows for clear images of nearby objects, but blurred distant vision. To correct the blurred distance vision, a diverging lens is used to make the light rays diverge to come to focus at a greater distance on the retina. Hyperopia, also known as farsightedness, occurs when the eye develops so that it is shorter in length than normal, resulting in light rays coming

to focus at a point beyond the retina and blurred near vision. Farsightedness is easily corrected with a compensating converging lens, which makes the light rays converge to a nearer focal point at the retina.⁸ A fourth condition of decreased visual acuity called presbyopia is also commonly noted in patients. Frequently developed as an eye ages past forty years, blurriness known as presbyopia can develop, because the ciliary muscles of the eye that control changes in lens shape gradually lose strength.⁹

Astigmatism, the main condition of concern when discussing achieving emmetropia after cataract surgery, is unlike myopia and hyperopia in that it involves irregular growth of the cornea rather than the overall length of the eye. The cornea is the exterior transparent covering of the eyeball and normally develops a regular convex shape (i.e. like a basketball cut along its median axis) during the ages between birth and four years; however, an astigmatic patient is a person whose cornea develops a more elongated curved shape (i.e. like a football cut midsagittally). Surprisingly, the cornea

actually carries out the majority of refraction of light rays entering the eye, as opposed to the lens of the eye. The lens plays a large role in refraction, but the

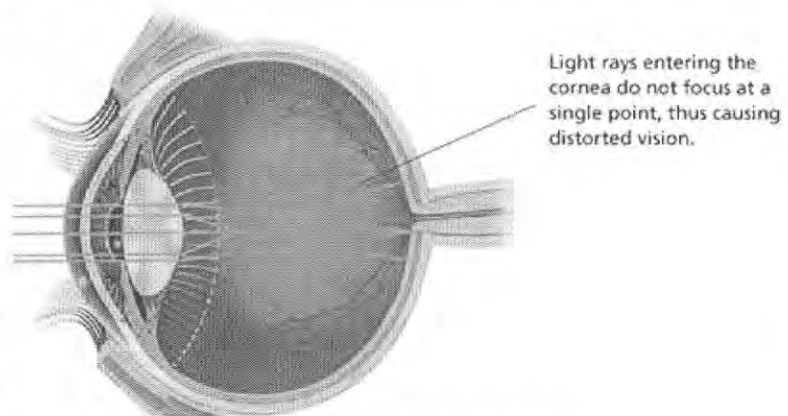
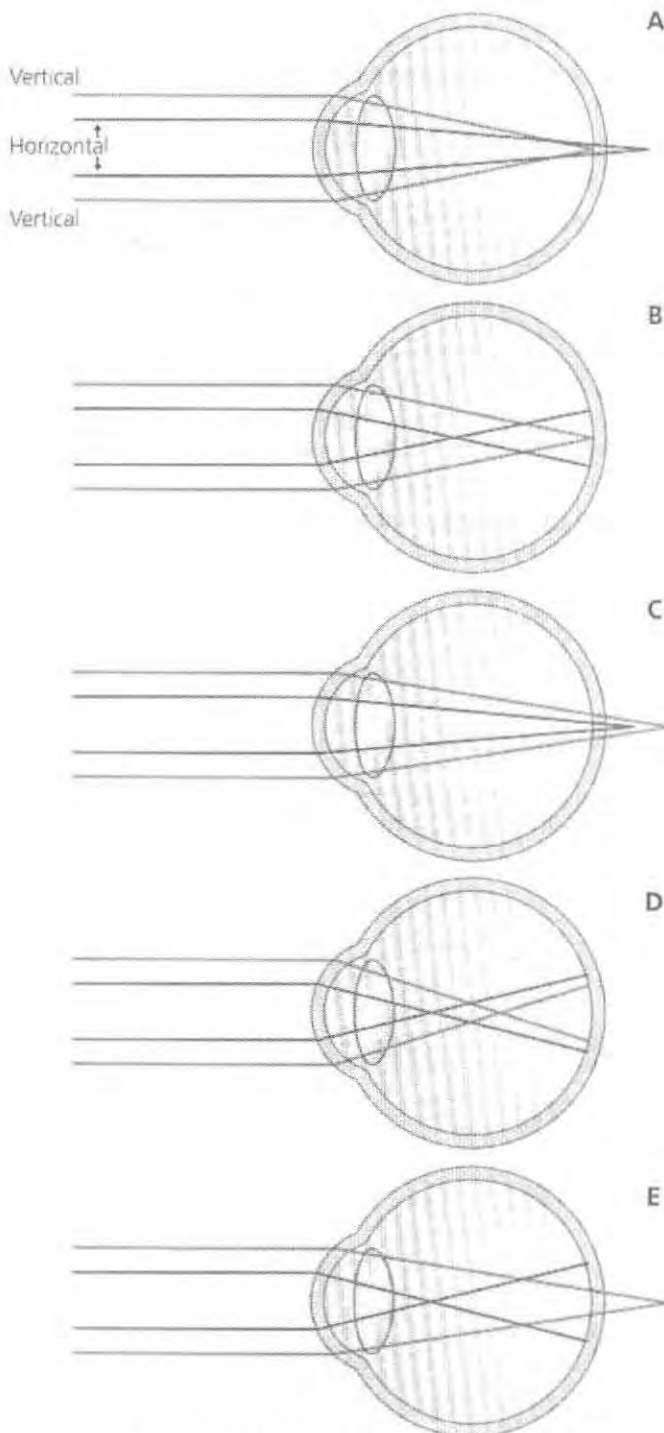


Figure 2. THE CAUSE OF THE ASTIGMATISM INDUCED BLURRINESS⁴

cornea plays an even more significant role in making sure light rays come to focus at a single point on the retina. Therefore, even a slight shift in the curvature of the cornea makes a significant difference in a patient's ability to focus objects both near and far

within their line of vision. At birth the human cornea is perfectly spherical. However, as the eye develops until age four, some corneas lose equality of the radius of curvature in all directions.⁴



The result of irregularities in the shape of the cornea is light being refracted unequally in all directions (Figure 2); consequently, a person suffering from astigmatism experiences blurriness in both near and far vision.⁸ The most common signs of astigmatism are the regular concurrence of squinting to see far away and holding reading material close to the eye to function in day-to-day life. Depending on the degree of irregularity of the cornea, there are two types of astigmatism: regular and irregular astigmatism. Characterized by minimal

Figure 3. THE THREE SUBCLASSES OF REGULAR ASTIGMATISM ARE SIMPLE (A and B), COMPOUND (C and D), AND MIXED (E).⁴

distortion of the corneal curvature, regular astigmatism is astigmatism that is possible to correct. Within the classification of regular astigmatism, there are three subclasses – simple, compound, and mixed (Figure 3). The subclasses of regular astigmatism are broken down into how the uneven refraction affects how light rays entering the eye come to focus. In simple regular astigmatism, some rays come to focus on the retina and others fall in front of or behind the retina. Compound regular astigmatism occurs when all focal rays either fall in front of or behind the retina, but not on the retina itself. However, mixed regular astigmatism is the case where the rays in focus fall in a mixture both in front of and behind the retina, but not on the retina.

On the other hand, there are some cases called irregular astigmatism where the curvature is so irregular that correction of the condition isn't possible. Irregular astigmatism occurs as a result of damage to the eye, most commonly by trauma, the development of scar tissue, inflammation of the eye, or extreme irregular development of the eye. In such cases, the cornea has become so asymmetrical that it is nearly impossible to create a lens to correct the resultant refractive errors.⁴

III. DIAGNOSING AND CORRECTING ASTIGMATISM

There are two primary methods optometrists and ophthalmologists utilize for diagnosing blurry vision as a case of astigmatism, including use of an astigmatic clock or a cross cylinder. Both the astigmatic clock and cross cylinder operate on the basis of determining the steep corneal meridian of an astigmatic eye, the axis on the cornea of highest diversion from the regular smooth convex shape of the anterior transparent covering. By determining the ridge of the cornea of highest irregularity, the doctor may then determine the best treatment option. If the steep corneal meridian is not too raised, then astigmatism is classified as regular, and ophthalmologists can fairly simply choose a compensating cylindrical lens that can fix the refraction errors. By the patient's choice, the compensating cylindrical lens can either be in the form of glasses or contacts.

The simpler of the two methods of determining whether or not a patient is suffering from astigmatism is the astigmatic clock. The astigmatic clock is considered a clock in that it is a chart that mimics the structure of a clock face by consisting of black

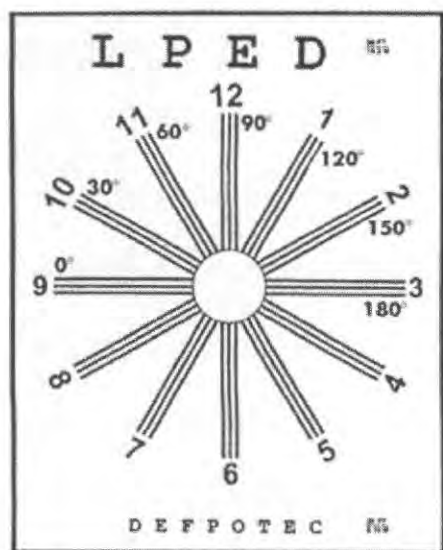


Figure 4. THE ASTIGMATIC CLOCK⁴

lines grouped in threes separated by 30° intervals to create an asterisk-like appearance (Figure 4). In order to determine the axis of the rays of light that are most in focus, the patient is seated at the normal distance for refraction of 20 feet and asked to select the darkest, sharpest line on the chart. The axis that is calculated to be 90° away from the darkest line can then be used by the physician as the correcting cylinder of the compensating cylindrical lens. In

order to adjust the placement of focus depending on the type of regular astigmatism (simple, compound, or mixed), two designations are used for the selected axis – plus or minus. A cylinder with a positive axis brings the focal point forward, if the astigmatism causes entering light rays to naturally fall behind the retina. On the other hand, a cylinder with a negative axis pushes the focal rays backward in order to correct for astigmatism that tends to refract light rays to focus on a point in front of the retina.

Although more complex in method, the use of a cross cylinder is the more accurate of the two methods utilized to diagnose astigmatism and is most often the preferred test of

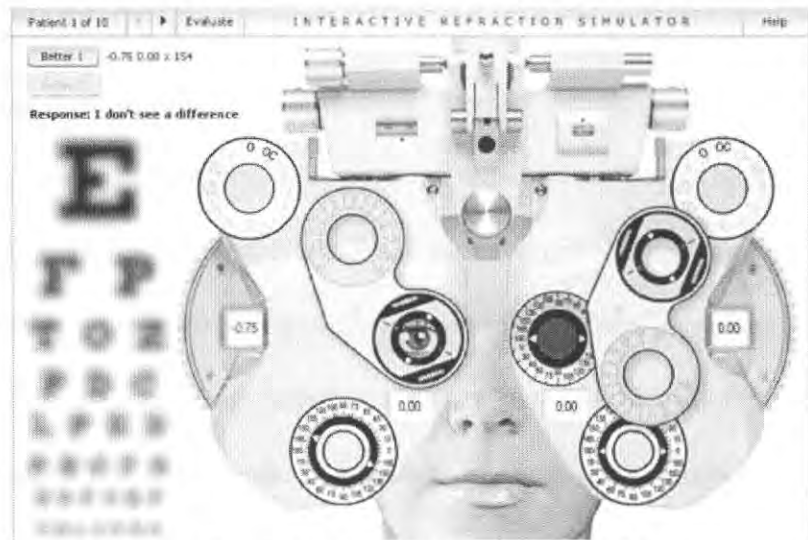


Figure 5. THE CROSS CYLINDER ⁴

physicians. A cross cylinder is a mounted lens consisting of two cylinders of equal power, but opposite designation (i.e. the designations plus or minus) having their axes set 90° apart in order to create a mixed astigmatism of equal amount, but opposite power in the two axes. Because the lens is mounted in a ring, it can be placed before a patient's eye that has been positioned at the refracting distance of 20 feet. With an eye chart placed before the patient, the physician then asks the patient to read a line of letters. By adjusting between varying axes and flipping back and forth from the two cylinders designated as choice "1" and "2" between readings of the line of letters, the patient can indicate which options provide for the most comfortable reading and the doctor may determine the axis

for the correcting cylinder. If one option appears better than the other, then the axis of the correcting cylinder is shifted in that direction. When options “1” and “2” become equally blurred for the patient performing the test, the physician may then recognize the correcting cylinder as correct for the compensating cylindrical lens.⁴

In addition to the use of a compensating cylindrical lens, the only other option for correcting astigmatism prior to the 1980s was the use of laser eye surgery, such as laser in situ keratomileusis (LASIK) or laser epithelial keratomileusis (LASEK). As described by its name, laser eye surgery is an elective out-patient surgical procedure that uses beams of light to reshape the cornea and, thereby, correct refractive errors that stem from that area of the eye. Because both LASIK and LASEK are elective procedures, they can be costly and are covered by very few insurance companies; therefore, the general treatment choice for patients suffering from regular astigmatism was to either wear glasses or contact lenses. It wasn't until Dr. Robert Osher's breakthrough in manipulation of the cornea during cataract surgery in 1983 that patients began having additional options for treatment. Besides the fact that the procedure has been shown to increase visual acuity, what also made Osher's cataract-related corneal treatment so exciting was that although cataract surgery is considered an elective procedure, most insurance companies recognize cataracts as disabilities and cover some, if not all, of the costs of surgical treatment.

IV. BACKGROUND ON CATARACTS

Most commonly found in patients over the age of 65, a cataract is a debilitating condition in which the lens of the eye gradually becomes darker in color and more




Figure 6. A) A NORMAL LENS,
B) A CATARACT LENS⁴

opaque over time (Figure 6).¹⁰ An additional case of cataract formation that is becoming increasingly more common is diabetes-induced cataractogenesis. With the irregular fluctuations of osmolarity that are a primary symptom of diabetes, the lens of the eye undergoes a great deal of stress, including periods of swelling and increased compaction of fibers in the nucleus.¹¹

At birth, a person's lens is naturally found to be perfectly translucent, and, as such, plays a large role in the refraction of light entering the eye. Another characteristic unique to an infant lens is the fact that it is soft in texture and significantly smaller in size compared to the normal adult lens. The outer membrane that initially serves to hold the putty-like fibers together is called the capsule;⁴ however, as an eye ages with the patient, the lens gradually hardens and lengthens both in height and width as more lens fibers are produced. Studies have shown that a normal human lens has the potential to increase in size up to 63% in equatorial diameter between birth and the age of 65.¹¹

With production of new fibers, the older fibers are pushed toward the center of the lens and eventually become concentrated to form a hardened area called the nucleus.⁴ As such, the central fibrous nucleus is believed to contain some of the oldest cells in the human body. However, the nucleus of the lens shouldn't be confused with the formation

of a cataract. Formation of a central nucleus is essential to normal functioning of the lens within the eye, because the compaction of cells in the nuclear region helps create the biconcave shape of the lens that is essential to normal refraction of light.^{11, 12} The issue of detriment due to cell compaction doesn't arise until certain factors are found to accelerate the processes of nuclear hardening and opacity to create a cataract. Once a cataract begins to harden and become cloudy due to a build up of compact fibrous cells, issues arise from light not being able to pass through the lens, a condition known as scattering.¹²

In addition to age and diabetes, other known factors that contribute to acceleration of fiber compaction within the nuclear area of the lens are smoking and UV light exposure. Both smoking and UV light induction of nuclear cataracts stem from oxidative damage due to production of free radicals.¹³ Other factors that are suspected of a role in cataractogenesis are obesity, genetics, and use of exogenous corticosteroids and estrogen.¹ Because there are so many factors that may potentially cause an increase in fiber production, almost all individuals eventually begin developing cataracts at some stage of their life. Whether or not cataract formation becomes an issue in a patient's lifestyle depends on the rate of fiber compaction and the time of initial onset.

Many patients develop cataracts very slowly, well after the normal onset of age 65, and, as a result, never face the issue of whether or not cataract surgery is a viable option. A cataract is considered mature when a patient deems that they can no longer tolerate the loss of vision due to scattering of light by the cataract. Again, cataract surgery is considered an elective procedure, in that it is up to the patient to decide when surgery is most necessary to improve their condition. The job of the ophthalmologist is to watch the

progression of cataract development in elderly patients, so that they may suggest action to correct the problem when vision impairment becomes a concern.

V. PRE-OPERATIVE CATARACT SURGERY PROCEDURE

Before diagnosis of either astigmatism or cataracts, all patients must undergo what is considered a routine eye exam, a series of tests consisting of refractometry, indirect examination, anterior examination, and an intraocular pressure check (Figure 7). By conducting these four examinations, a physician inspects the overall health and

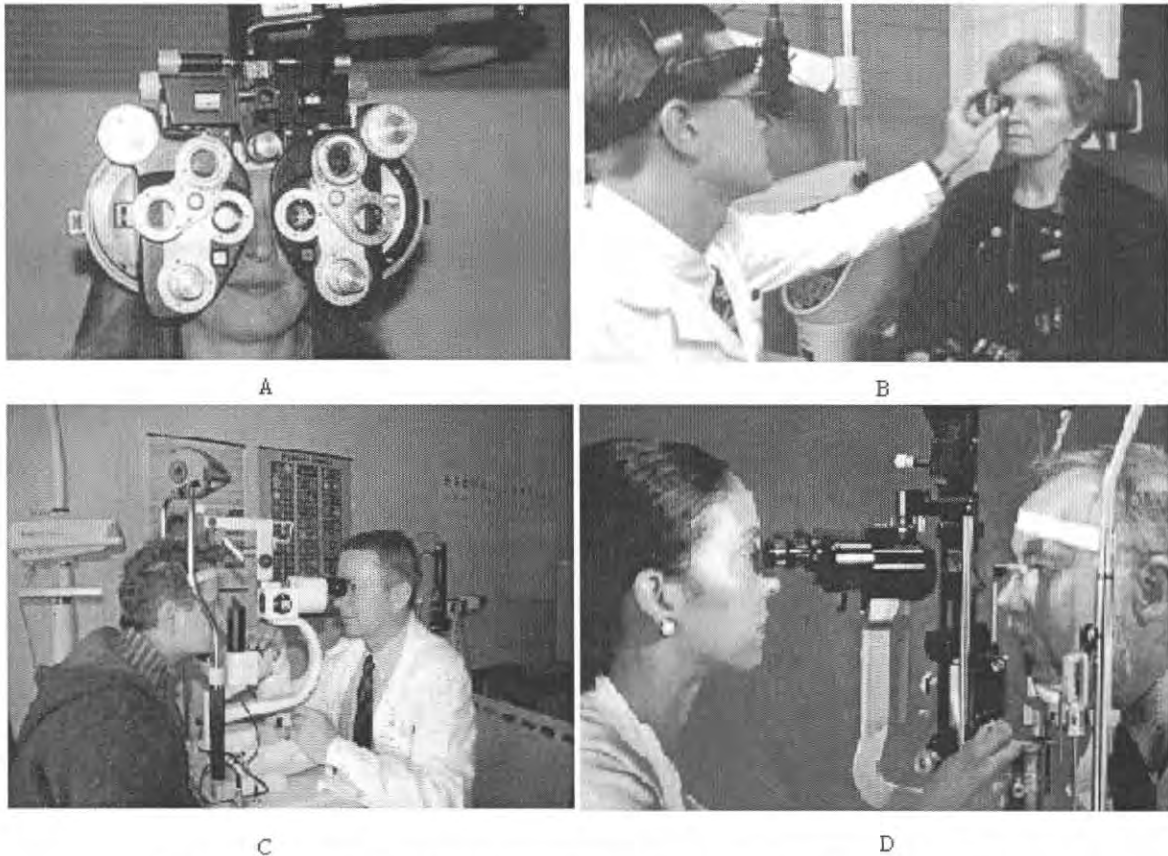


Figure 7. ROUTINE EYE EXAM PROCEDURES: A) REFRACTOMETRY, B) INDIRECT EXAMINATION, C) ANTERIOR EXAMINATION, D) INTRAOCULAR PRESSURE CHECK⁴

wellness of the eye, in addition to determining the patient's visual acuity. Prior to any examination by an ophthalmologist or their assistants, patients are given cycloplegic drops in both eyes. Cycloplegia is the impairment of the ciliary muscle of the eye, which is the muscle responsible for controlling accommodation of the eye. Through induction of temporary cycloplegia (lasting between 4 to 6 hours) over the period of examination, the doctor achieves two goals – preventing accommodation by the patient during

examination and allowing the eyes to dilate sufficiently to allow for a retinal evaluation in the indirect examination.⁴

A. Refractometry

The first examination called refractometry is the method a physician uses to determine the baseline visual acuity of a patient. As suggested previously, visual acuity (VA) is the ability of a patient to focus on objects within both their near and far fields of vision. Visual acuity can vary sizably from visit to visit, depending on a person's age and health, so it is very important that a doctor monitor the changes over time and suggest treatment options for cases of declining vision. The instrument utilized in refractometry, a phoropter is a set of lenses mounted on a circular wheel that can be placed before a patient's eyes in order to determine their ability to bring objects to focus.

The normal distance for performing refractometry is 20 feet, because that is the distance at which light rays are parallel when entering the eye and, therefore, little accommodation is needed in order to form a crisp image from the rays coming to focus. A Snellen chart, consisting of a triangle of rows of letters, is typically projected on a wall in the examination room utilizing mirrors to simulate a distance of 20 feet from the patient. The phoropter is placed before the patient's eyes and the patient is asked to read what they can distinguish from certain lines of letters. Visual acuity is reported as a fraction (i.e. 20/20, 20/40, 20/60, etc.) where the numerator is the actual distance of the patient from the letters discerned and the denominator indicates the patient's ability to distinguish the letters compared to a person with normal vision.⁴ For example, if a physician deduces that a patient can see "20/60," the indication is that the patient was seated 20 feet away from the Snellen chart, but could only make out a row of letters at 20

feet that a person could normally see at 60 feet. On some occasions, vision may decrease beyond the use of a Snellen chart. In such cases, the focus then shifts to whether or not a patient can sense the presence of the physician's raised fingers, hand movement only, or light detection only. Because refractometry is the process of determining a patient's refraction errors, it is during this examination that a doctor typically uses a cross cylinder to diagnose astigmatism and prescribe the best compensating cylindrical lens.

B. Indirect Examination

Besides using refractometry to determine the refraction errors of an eye, it is also important for a physician to investigate the current health of the interior parts of the eye, such as the retina and the optic nerve. Once light rays come to focus on the interior back surface of an eye, the nerve cells located within the retina known as rods and cones pass information collected from the light as nerve impulses to the brain through the optic nerve. Phototransduction is the process of conversion of light to nerve impulses from the rods and cones for transfer through the optic nerve to the brain.⁷ Because decreases in visual acuity may be caused by many things besides myopia, hyperopia, presbyopia, and astigmatism, it is important for the physician to study the inside of the eye to make sure there aren't problems with the phototransduction process.

With a properly dilated eye, an ophthalmoscope is the instrument that physicians utilize for examining the posterior regions of the eye. There are two types of ophthalmoscopy that can be employed – direct and indirect. Despite the fact that it produces an image that isn't upright and is of a smaller magnification than an image from direct ophthalmoscopy, an indirect ophthalmoscope is generally preferred. Ophthalmologists generally prefer an indirect ophthalmoscope to a direct

ophthalmoscope due to the fact that it leaves the hands free during the procedure, allows greater illumination of the fundus (the surface within the eye, opposite of the lens), provides depth perception, and most importantly creates a larger field of view, so that the physician can study a greater portion of the back of the eye. When conducting an indirect examination, a head-lamp is placed on the head of the physician and a +20.00 diopter convex lens is utilized to reflect the light from the head-lamp into the patient's eye. From a sitting distance of around 15 inches from the eye under investigation, the physician instructs the patients to gaze periodically in all four quadrants (left, right, up, and down) so that a large portion of the eye can be examined, including the cornea, lens, optic nerve, retinal arterioles and veins, as well as all parts of the peripheral retina. During indirect ophthalmoscopy quite a bit can be ascertained about the condition of an aging lens, including whether or not a cataract has begun forming. Since the lens is toward the anterior part of the eye, the development of a cataract obscures a large portion of the fundus and is quite plain to diagnose.

C. Anterior Examination

While indirect ophthalmoscopy is used to study the posterior portion of an eye, a slit-lamp microscope is utilized to examine the anterior portions of the eye to make sure they remain in good health and aren't contributing to degradation of visual acuity. Parts of the anterior region of the eye studied with a slit-lamp microscope are the lens, iris (the colored portion of the eye which undergoes contraction in response to bright light), cornea, sclera (the white region on the exterior of the eye that serves in protection), conjunctiva (a mucous membrane that covers the sclera to provide protection against damage to the cornea), and lids. Although a cataract may be identified through the use of

indirect ophthalmoscopy, better inspection of the lens of an eye is carried out through the use of a slit-lamp microscope. The anterior examination equipment provides higher magnification and illumination of the area than that provided by an ophthalmoscope.

In addition to the eyepiece through which the physician looks to study the eye, the microscope is fitted with a chin and forehead rest that the patient's head is placed against in order to carry out a thorough examination. The light from the microscope is directed as a thin beam of light onto the cornea while the doctor directs his field of view of the anterior regions of the eye using a control knob similar to a joystick.

D. Intraocular Pressure Check

In addition to studying the anterior regions of the eye, such as the lids, sclera, and the cornea, a slit-lamp microscope can also be employed to check the intraocular pressure of an eye if the microscope has an attachment of an applanation tonometer. High intraocular pressure is a sign of glaucoma, a debilitating disease caused by retinal neuropathy; therefore, patients receive a pressure check for each eye during every routine eye exam administered. The basis of a pressure check with an applanation tonometer is application of slight pressure on the center of the cornea by a biprism suspended on a rod. Pressure within the eye is determined by the amount of corneal area that is flattened by pressure from the biprism. The smaller the area flattened by the biprism, the higher the intraocular pressure.⁴ A normal eye has an intraocular pressure ranging from 10 to 20 mmHg; therefore, consistently high intraocular pressure over 20 mmHg is a cause for concern.

Once a patient's eyes have been inspected by refractometry, indirect examination, anterior examination, and an intraocular pressure check, it is up to the ophthalmologist to

determine the best treatment options for any conditions identified. If a patient has a cataract that seems to have reached maturity, the focus of the ophthalmologist shifts from the ideal of maintaining optimum vision in spite of the condition to proposing intraocular lens correction through cataract surgery. Some patients choose against having cataract surgery, because of the worry that there might be complications or the prospect of facing prolonged debilitation during the post-operation recuperation. However, cataract surgery is a widely misunderstood procedure in that sense. In fact, cataract surgery is a relatively quick and painless practice generally requiring 10 to 30 minutes to complete and usually results in an average of only about a week of slight discomfort in the eye (most often described by patients as scratchiness).

The overall objective of cataract surgery is removal of the opaque nucleus of the natural lens and insertion of a new artificial lens through a small incision along the cornea of the eye. Unless the gradual loss of vision that accompanies development of a cataract really becomes a nuisance to a patient, most surgeons prefer to suggest surgery later, rather than sooner in the process of cataractogenesis. Nothing can compare to the natural lens of the eye, although biomedical engineering has become successful in creating extremely sophisticated synthetic replacement lenses. Also, most ophthalmologists find that the more mature a cataract is, the easier and cleaner the process is of removing the nucleus from the epinucleus. In speaking about the readiness of a cataract to be removed, ophthalmologists usually refer to it as a cataract's "ripeness."

When the lens is observed to be critically opaque, lacking clarity of color, and the patient can no longer tolerate the resultant decrease in visual acuity, cataract surgery is scheduled as an outpatient procedure either at a hospital or the ophthalmology clinic.

Although the number of ophthalmology clinics with in-house cataract surgery equipment is rising, most hospitals have the equipment necessary for carrying out the procedure. Cataract surgery is an outpatient procedure in that a patient is normally checked in for the operation early in the morning, prepped for surgery over a period of about an hour, undergoes the procedure for a relatively short period of time (in comparison to other surgeries), and then is released before the late morning. Depending on the surgeon and the specifics of the case, the operation can take anywhere between 10 to 30 minutes, but a patient can normally expect to be at the hospital or clinic for no longer than a few hours.

The concision of cataract surgery stems primarily from the development of the microincision technique. Over time, physicians have persistently worked on improving the surgical technique by trying to minimize the incision size along the cornea. Over a time span of almost fifty years (since the development of the phacoemulsification procedure in cataract surgery), the incision length has decreased from an average of 11 mm (which correlates to a 150 degree span along the axis of the eye) to a mere 2.5-3 mm.⁴ Besides allowing for a quicker surgical procedure, the decrease of incision size most importantly results in less tissue destruction, smaller risks of complications, quicker recovery times, and minimal surgically induced astigmatism.¹⁴ With the use of smaller incisions, ophthalmologists eliminated the need for closure of the incision with sutures and the procedure has developed into one of minimal bleeding. Cataract lenses of a patient's eyes are always operated on at separate occasions, even if a patient is suffering from simultaneous decreased visual acuity in both eyes. In doing so, the ophthalmologist allows the patient to gain optimal vision in one eye, so there is never a period of complete visual incapacitation after surgery.

In order to best plan the surgical procedure technique, two additional tests are conducted prior to cataract surgery – A-scan and photokeratoscopy. A-scan is a technique that uses a probe to determine the axial length of the eye, so that the lens power of the required synthetic, intraocular replacement lens can be accurately determined. Photokeratoscopy is the procedure of using a computer to create an image of the topography of a patient’s cornea. Prior to the 1980s, computerized corneal topography was generally only taken prior to a patient expressing interest in having general refractive surgery. But with the development of “refractive cataract surgery” through astigmatic keratotomy, many ophthalmologists have shifted their use of photokeratoscopy to also encompass pre-operative cataract surgery procedure. In the interest of correcting astigmatism in the process of replacing an aged lens, the natural curvature of the cornea is assessed. In order to determine a cornea’s divergence from a natural curvature, the patient is seated before a lighted, bowl-shaped grid. When the illuminated grid passes onto the surface of the person’s cornea and is reflected, the reflection is captured by a camera that can sense the changes in the reflection from the original grid and can, therefore, recognize the overall topography of the cornea. The image that is printed by the equipment is a colored topograph, in which the surgeon can recognize areas of higher topography as red regions and areas of lower topography as blue regions.⁴

Once a patient’s astigmatism is calculated based on the computerized reading by the photokeratoscopy, the surgeon then must consider what technique would be in the best interest for the patient. In 1998, there was an additional breakthrough in astigmatism correction with the development of synthetic intraocular lenses (IOL) called toric lenses, which correct a degree of preexisting astigmatism when utilized during cataract surgery.

Although toric IOLs are a great advancement for the prospect of achieving emmetropia through cataract surgery, there are some drawbacks to their use. Toric lenses have only been developed to correct up to 3.00 diopters of astigmatism,¹⁵ and because they are so new on the market, the use of the IOLs poses additional costs to the overall price for surgery. As such, it has become the norm for surgeons to employ either a combination of a toric lens with astigmatic keratotomy (in cases of astigmatism over 3.00 diopters) or only astigmatic keratotomy (when the added cost of a toric lens isn't a practical option for the patient). Prior to surgery, ophthalmologists skilled in the procedure of astigmatic keratotomy must then sit down with the patient's chart of test results. They must carefully weigh the patient's options of whether to proceed with implantation of a normal IOL combined with astigmatic keratotomy, solitary use of a toric IOL, or the combined use of a toric IOL with astigmatic keratotomy.

VI. METHOD OF REGULAR CATARACT SURGERY

Prior to the development of astigmatic keratotomy and the toric IOL, all cataract surgery patients underwent the same general procedure. Because the only option for people with astigmatism was to wear contacts or glasses after surgery, the surgeon would follow a standard procedure of replacing the cataract with a synthetic lens meant to correct myopia or hyperopia. Before the operation, the skin around the eyelid including the eyebrow would be cleaned with an antiseptic such as povidone-iodine. After cleaning the exterior regions of the eye, the eye was irrigated with dilute Betadine and balanced saline solution. Then anesthesia was administered to prevent any discomfort during the surgery. Both a topical anesthetic of tetracaine was applied and there was an injection of 0.25-0.5 cc of 1% lidocaine into the anterior chamber to numb the eye and prevent shutting of the eyelids. Once the eye became completely numb, the eye was held open with fixation forceps and the 2.5-3.0 mm incision was made in the same general area along the temporal region of the cornea, regardless of the condition of the corneal topography. Additional balanced saline solution was then injected through the incision to separate the nucleus of the lens from the epinucleus. Although the opaque nucleus was removed during surgery, the epinucleus was left behind to prevent rupture of the posterior capsule of the eye.

In order to skillfully remove the hardened nucleus through the incision without tearing the incision in the process, a phacoemulsification technique was developed in 1967 to break up and slowly soften the hardened cataract with a steel probe that vibrates at ultrasonic frequencies. Customarily, the physicians divided the nucleus into four relatively equal segments by drawing two lines perpendicular through the center of the

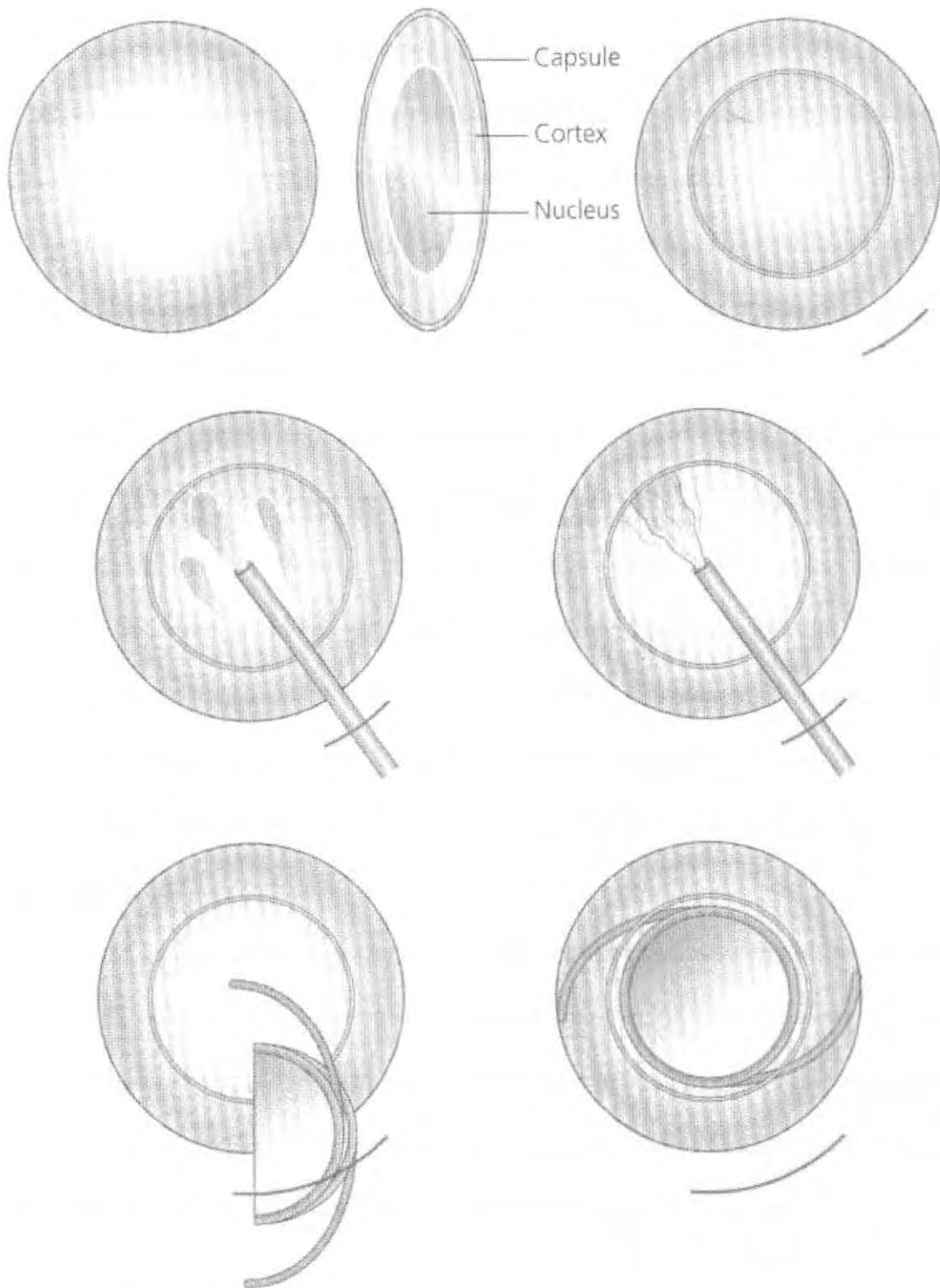


Figure 8. REGULAR CATARACT SURGERY PROCEDURE ⁴

cataract with the probe. Once the toughest parts of the nucleus were emulsified with the phaco probe, the probe was removed and an aspirator was inserted through the incision to remove the loosened remnants of the nucleus. In the process of removing the broken up nucleus, the softer outer region of the lens called the cortex could also be suctioned out utilizing the aspirator. The remaining epinucleus underwent a final polishing with the suction probe to remove any trailing lens fibers and then the pocket was ready for implantation of a synthetic IOL.

There are two general parts of synthetic intraocular lenses – the optic and the haptic. The optic is the transparent, circular part of the lens through which light passes before coming to focus on the retina. Loops made from either proline or polymethylmethacrylate, the haptics are tiny extensions from the optic that are intended to hold the lens in the correct position after implantation. The development of acrylic and silicon-based IOLs has permitted sufficient flexibility in the structure of the synthetic lenses to allow them to be placed through the incision by means of being folded twice within a pair of micro-forceps.

In the general cataract surgery technique, the lens was inserted, slowly unfolded, and the IOL was positioned within the posterior chamber of the eye where the natural lens was originally found. The corneal incision sealed off on its own over a period of few hours, because the internal lip created in the cornea naturally closed off with adjusting intraocular pressure changes after surgery (Figure 8).⁴

VII. METHOD OF “REFRACTIVE” CATARACT SURGERY

Little has changed in the pre-operative and post-operative techniques in the newly developed procedure of “refractive” cataract surgery. The eye being operated on is initially prepped with povidine-iodine, Betadine, balanced saline, tetracaine topical anesthetic, and an injection of 0.25-0.50 cc of 1% lidocaine. The primary difference in procedure between regular cataract surgery and “refractive” cataract surgery is the use of one or two additional corneal incisions utilized to flatten the irregularity of the corneal topography, the technique called astigmatic keratotomy. Developed by Dr. Robert Osher in 1983, astigmatic keratotomy is the technique of utilizing incisions known as limbal relaxing incisions (LRIs) to reshape the cornea in the process of phacoemulsification.¹⁶ The term “limbal” is derived from the word “limbus,” which is the scientific term for the

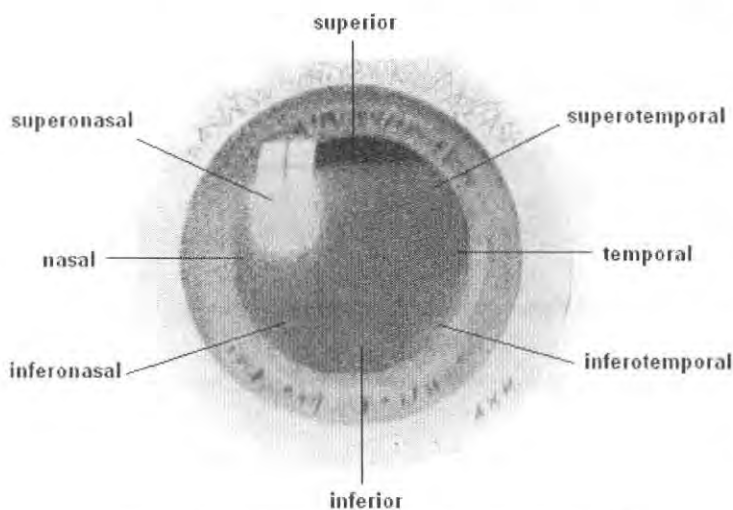


Figure 9. THE EIGHT CORNEAL REGIONS⁴

outermost edge of the cornea. “Relaxing” refers to the fact that the purpose of the technique is to use the additional incisions to flatten out the irregular curvature of the cornea. There are eight general corneal regions classified by ophthalmologists – superior, superotemporal, temporal, inferotemporal, inferior, inferonasal, nasal, and superonasal (Figure 9). However, when deciding the best axis for a limbal relaxing incision to decrease the preexisting corneal-derived astigmatism, physicians use an axis of 360 degrees. If the physician inspects a

chart and deems that astigmatic keratotomy could be a beneficial addition to the patient's cataract surgery procedure, there are two primary things that must be taken into consideration when deciding the axis of the limbal relaxing incision. Within the eight general corneal regions, studies have shown that some regions are better than others for LRIs, regardless of the eye involved. Any incision in the cornea induces some degree of astigmatism. Depending on the region of the cornea where incision takes place, the surgically induced astigmatism can be negligible or rather significant. The superior and superotemporal regions of the cornea have been shown to induce negligible additional astigmatism (i.e. 0.20 to 0.37 D) during cataract surgery, compared to an average of 1.00 D or more with use of the six other regions.^{17, 18}

Besides utilizing the superior or superotemporal regions of the corneas for LRIs, the doctor must also carefully study the topographic images acquired from the photokeratotomy readings taken prior to surgery. In photokeratotomy the computer calculates the steep corneal meridian, which is indicated on the topographic image as the axis containing the majority of the red shading on the map. The best case scenario is where a patient's steep corneal meridian runs through either the superior or superotemporal regions. One or two LRIs can be placed along the steep corneal meridian in addition to the incision through which the cataract is removed and the synthetic lens is inserted. About 2.00 D of astigmatism can be eliminated with each LRI, so one or two incisions are made based on the case. No more than 4.00 D of total elimination with LRIs has been found possible, so it isn't customary for an ophthalmologist to make more than two LRIs. If the patient has more than 4.00 D of astigmatism prior to cataract surgery, it is necessary to use a toric lens in addition to astigmatic keratotomy to totally eliminate

the astigmatism.¹⁵ Most often, a person's steep corneal meridian doesn't fall within the superior or superiotemporal regions of the cornea. In such a case, LRIs can still be used to decrease the irregularity of the cornea, but there is a trade off. By placing the LRI in a region other than the two optimum regions, the LRI itself will induce at least 1.00 D of astigmatism and the LRI will only be about 50% efficient.

Once the corneal incisions are made, the surgery precedes as regular cataract surgery would. The nucleus is separated from the epinucleus by injection of balanced saline through the primary incision. The nucleus may then be emulsified with the phaco probe by using two cross-section grooves to break the hardened cataract into four wedges that can be degraded easier by the ultrasound and removed from the pocket by the aspirator. Once the nucleus and the soft cortex are removed, the epinucleus is polished with the phaco probe and the folded synthetic lens is placed in the posterior chamber of the eye. Again, the incisions created in the cornea don't require sutures to seal the chamber and gradually heal. The natural intraocular pressure changes that occur within the eye gradually seal off the incisions created within the cornea.

Once cataract surgery is complete, the eye is patched to prevent rubbing or any potential pressure on the eye. It is the tendency for patients to want to rub the eye, because the most common sensation felt after cataract surgery is irritation in the eye, rather than any significant pain. In addition to prevention of any direct pressure on the eye, it's also extremely important to keep the eye as closed off to the environment as possible at least for the first couple of days. Patients are advised not to wear any eye make-up and keep the eye covered in order to lessen the chance of infection after surgery. All patients undergo a series of post-operation visits, so that the doctor can monitor the

healing progress of the eye. Usually doctors require post-operation visits after 4-6 hours, 1 week, and after 2-4 weeks. After one week, all post-operation discomfort within the eye should have disappeared. And after 2-4 weeks have passed, the patient discontinues antibiotic treatment and the visual acuity of the eye will have stabilized. There are three general medications routinely prescribed after a patient undergoes cataract surgery – an antibiotic drop to reduce the risk of infection (i.e. Vigamox), a steroidal drop to decrease inflammation (i.e. Pred Forte or Flavex), and a nonsteroidal drop to reduce the risk of a condition known as cystoid macular edema (i.e. Acular).⁴

VIII. CONCLUSIONS

The development of the procedure of astigmatic keratotomy by Dr. Robert Osher in the 1980s truly revolutionized the field of cataract surgery. For the first time in the history of lens replacement there was the prospect of an astigmatic patient healing from cataract surgery to find no need for glasses or contact corrections. Dr. Osher's ideas totally shifted the mindset of the ophthalmology community from the ideal prospect of cataract surgery being best spectacle-corrected visual acuity to best uncorrected visual acuity. Astigmatic keratotomy was one of the most significant breakthroughs of the second half of the twentieth century within the field of ophthalmology. Despite being accused of malpractice by his peers for attempting to meddle with the cornea throughout the early development phases of astigmatic keratotomy, Dr. Osher could sense the promise behind his ideas and continued to push forward with experiments to test the prospect of correcting irregularities of the curvature of the cornea.

Through the Carl Goodson Honors Council, I received the honor of being named the Ben Elrod Scholar of the 2007-2008 school year and was awarded funds to further my research on astigmatic keratotomy in observation of ophthalmologists that use limbal relaxing incisions. Upon contacting Dr. Osher of the Cincinnati Eye Institute, he graciously extended me an invitation to visit his ophthalmology practice in Cincinnati and observe him utilizing the technique that he had developed. As a result, in May of 2008 I got the opportunity to travel to meet Dr. Osher and interview him about his life and the extraordinary breakthroughs he has made in the field of cataract surgery. He invited me to his home and allowed me to experience first-hand the pre-operative thought process that goes into determining the best procedure to pursue with each cataract surgery

case. Furthermore, I was able to visit the Cincinnati Eye Institute and observe Dr. Osher perform astigmatic keratotomy within the cataract surgery procedure.

While observing Dr. Osher in surgery, I found him to be the epitome of compassion and hard-work. His bottom line is giving the patient the best results possible. It is through that mindset that he was able to overcome the adversity he faced during the preliminary stages of developing the new field of “refractive” cataract surgery and eventually complete the first successful corneal reshaping utilizing limbal relaxing incisions in 1983. With continued success of the astigmatic keratotomy procedure throughout the late 1980s, the reception of the once earth-shattering idea began to change. Ophthalmologists began taking notice of the Cincinnati Eye Institute. Prominent ophthalmologists around the world started investigating the new procedure and soon began requesting training in the radical new technique. By the late 1990s and early twenty-first century, there were countless clinics spanning the globe routinely using astigmatic keratotomy.

Besides the exciting prospect of complete astigmatic correction with LRIs, another truly fascinating aspect of Dr. Osher’s ground-breaking technique is its selflessness. With the development of toric lenses in the 1990s came another option for astigmatism correction during cataract surgery. Although expensive, a toric IOL can similarly correct up to 4.00 D of astigmatism. Therefore, after the development of both astigmatic keratotomy and toric IOLs, the question for ophthalmologists became whether to simply implant a toric lens or correct the corneal shape with manual use of LRIs.¹⁵ The ophthalmologist could help the patient achieve the same visual acuity with either technique. However, the use of astigmatic keratotomy is cost-free, while the price range

of toric lenses is \$600 to \$1,500 in addition to the overall cost of cataract surgery. Also, even more fundamental is the issue of the use of astigmatic keratotomy resulting in the loss of revenue from post-cataract operation sales of prescription glasses and contacts. The continued use of LRIs in spite of such revenue losses is nothing short of gallant. The fact that ophthalmologists are continuing to use astigmatic keratotomy, regardless of the losses they take in the long run just shows that goodness and integrity still reign true in society.

IX. REFERENCES

1. Abraham, A. G., N. G. Condon, and Gower E. West. "The New Epidemiology of Cataract." Ophthalmology Clinics of North America 19(2006): 415-425.
2. Congdon, Nathan. "Prevalence of Cataract and Pseudophakia/Aphakia Among Adults in the United States." Archives of Ophthalmology 122(2004): 487-494.
3. Elliott, Jane. "The Romans Carried Out Cataract Operations." BBC News February 9, 2008. January 20, 2009. <http://news.bbc.co.uk/2/hi/health/7194352.stm>.
4. Stein, Harold A., Raymond M. Stein, and Melvin I. Freeman. The Ophthalmic Assistant. 8th ed. Ontario: Elsevier Mosby, 2006.
5. Woodcock, Malcolm, Sunil Shah, and Ronald J. Smith. "Recent Advances in Customizing Cataract Surgery." BMJ. 328(2004): 92-96.
6. Osher, Robert H. "Astigmatic Surgery: A Personal Tale." Cataract and Refractive Surgery Today 5(2006).
7. Silverthorn, Dee U., William C. Ober, Claire W. Garrison, Andrew C. Silverthorn, and Bruce R. Johnson. Human Physiology. 4th ed. San Francisco: Pearson Education, Inc., 2007.
8. Giancoli, Douglas C. Physics: Principles with Applications. 6th ed. Upper Saddle River: Pearson Education, 2005.
9. Wise, Eric. Anatomy and Physiology Laboratory Manual: The Unity of Form and Function. 4th ed. New York: McGraw-Hill, 2007.
10. Bram, Leon L. "Cataract." Funk and Wagnalls New Encyclopedia. 1986.
11. Freel, Christopher D., Kristin J. Al-Ghoul, Jer R. Kuszak, and M. Joseph Costello. "Analysis of Nuclear Fiber Cell Compaction in Transparent and Cataractous Diabetic Human Lenses by Scanning Electron Microscopy." Biomed Central Ophthalmology 3(2003): 1-9.
12. Al-khudari, Samer, Sean T. Donohue, Walid M. Al-Ghoul, and Kristin J. Al-Ghoul. "Age-related Compaction of Lens Fibers Affects the Structure and Optical Properties of Rabbit Lenses." Biomed Central Ophthalmology 7(2007): 1-14.
13. Nicita-Mauro, Vittorio, Giorgio Basile, Giuseppe Maltese, Claudio Nicita-Mauro, Sebastiano Gangemi, and Calogero Caruso. "Smoking, Health, and Ageing." Immunity and Ageing 5(2008): 1-4.

14. Guiaro, Antoinio, Jaime Tejedor, and Pablo Artal. "Corneal Aberrations before and after Small-Incision Cataract Surgery." Investigative Ophthalmology and Visual Science 12(2004): 4312-4319.
15. Osher, Robert H., Roger F. Steinert, Louis D. Nichamin, Kevin L. Waltz. "Correcting High Astigmatism During Cataract Surgery." Cataract and Refractive Surgery Today 2(2008): 27-28.
16. Osher, Robert H. "Paired Transverse Relaxing Keratotomy: A Combined Technique for Reducing Astigmatism." Journal of Cataract and Refractive Surgery 15(1989): 32-37.
17. Wallace, R. Bruce. "Where is the Axis?: The Surgical Correction of Astigmatism." Cataract and Refractive Surgery Today 5(2006): 55-56.
18. Guiaro, Antoinio, Jaime Tejedor, and Pablo Artal. "Corneal Aberrations before and after Small-Incision Cataract Surgery." Investigative Ophthalmology and Visual Science 12(2004): 4312-4319.